

Histopathological study in Lungs of mice implanted with mammary adenocarcinoma (AM3) and treated with flavonoids (apigenin)

Zainab Ismail Ibrahim *

Zainab Jamal Mohammed Jawad*

Layla Hashim Alo**

*Department Of Pathology And Poultry Diseases, ** Department Of Physiology And Pharmacology, College Of Veterinary Medicine / Baghdad University- Iraq.

E.mail:zainabalrubaei@yahoo.com

Abstract:

Several studies have demonstrated that the anticarcinogenic properties of apigenin occur through regulation of cellular response to oxidative stress and DNA damage, had a role as anti-oxidant activity and regulate the redox status and prevent damage caused by oxidative stress. The present study aimed to investigate the histopathological changes may occurred in pulmonary tissues of mice implanted with mammary adenocarcinoma AM3 and treated with flavonoid. A sixty mice bearing-mice tumor and normal mice divided into G1; (n=3) bearing-AM3 tumor and treated with flavonoids (apigenin) 300mg/kg b.w/orally and daily/30 days, G2; (n=3) mice bearing-tumor only, G3; (n=5) mice treated with flavonoids (apigenin) 300mg/kg b.w/orally /30days, G4; (n=5) as control group treated with D.W. The results of hematoxyline and eosin stained tissues of lung revealed significant histologic changes in tumor-bearing mice of chronic bronchiolitis, interstitial pneumonia and alveolar emphysema, while in treated bearing-mice with flavonoid showed perivascular cuffing, no metastasis seen.

Conclusion; apigenin has a significant anti-neoplastic role against implanted tumor to prevent infiltration and invasion of tumor cells to distant region.

Key words: *flavonoid (apigenin)*, anticancer efficacy, histopathological changes in mammary adenocarcinoma.

دراسة التغيرات المرضية النسجية في رئة الفئران المغروسة بسرطانة الغدة اللبنية والمعالجة

بالفلافونويد

زينب اسماعيل ابراهيم⁽¹⁾ زينب جمال محمد جواد⁽¹⁾

ليلى هاشم علو⁽²⁾

فرع الامراض وامراض الدواجن⁽¹⁾، فرع الادوية والسموم⁽²⁾، كلية الطب البيطري / جامعة بغداد.

المستخلص:

بينت دراسات عديدة خصائص المستخلص النباتي الفلافونويد كمضاد للسرطان وذلك من خلال تنظيم الاستجابة الخلوية لعوامل الاكسدة وتلف الحمض النووي DNA، بالإضافة الى دوره المهم كمضاد اكسدة وتنظيم عملية الاكسدة من خلال تحطيم عوامل الاكسدة. لذا هدفت الدراسة الحالية الى التحري عن التغيرات المرضية النسجية الحاصلة في الانسجة الرئوية للفئران المغروسة بسرطانة الغدة اللبنية والمعالجة بالفلافونويد. استخدم في التجربة ستة عشر فئران من الحاملة للسرطان والاخرى طبيعية، قسمت الى المجموعة الاولى (عدد 3) من الفئران الحاملة

لسرطانة الغدة اللبئية والمعالجة بالفلافونويد (300 ملغم/كغم من وزن الجسم) يوميا طيلة 30 يوما، المجموعة الثانية (عدد 3) حاملة للورم فقط ، المجموعة الثالثة (عدد 5) من الفئران الطبيعية تمت معالجتها بالفلافونويد (300 ملغم/كغم من وزن الجسم داخل الفم /30 يوما، المجموعة الرابعة (عدد 5) مجموعة سيطرة اعطيت الماء العادي فقط . اظهرت الانسجة الرئوية المصبوغة بالهيماتوكسلين والايوسين تغيرات نسيجية مهمة في الفئران الحاملة للورم من التهاب القصيبات المزمن والتهاب الرئة الخلالي مع النفاخ الرئوي ، بينما ظهر في الفئران الحاملة للورم والمعالجة بالفلافونويد التكفف الوعائي ولم يظهر نقائل ورمية دموية.

الاستنتاج: الفلافونويد له تاثير مضاد للسرطان في الفئران الحاملة للورم ومنع ارتشاح وغزو الخلايا السرطانية الى اعضاء اخرى.

الكلمات المفتاحية: الفلافونويد ،التاثير المضاد للسرطان، التغيرات المرضية النسيجية في سرطانة الغدة اللبئية.

Introduction:

The recent studies revealed the efficacy of apigenin to promote cell cycle arrest and induction apoptosis through the p53-related pathway, a further role of apigenin in chemoprevention is the induction of autophagy in several human cancer cell lines (11). Flavonoids could be excellent candidates as protective agents against radiation-induced lung injury (12). Apigenin induces autophagy (a kind of cellular waste-recycling system) in leukemia cells, which may support a possible chemo-preventive role. Autophagy interferes with the action of the chemotherapy drug vincristine (7).

To improve these facts the present study aimed to investigate the histopathology changes of pulmonary tissue in mice bearing mammary adenocarcinoma treated with or/and without flavonoid.

Materials and Methods:

1-Flavonoid extraction and identification: according to (1) and the Preparation of Flavonoid dose (300mg/kg B.W) according to (2).

2-Lab animals: mammary adenocarcinoma (AM3) bearing mice and normal mice from Iraqi Center for Cancer and Medical Genetic Research (ICCMGR).

3- Experimental design: both strains of mice divided randomly to four groups as following:

1st group: (n=3) AM3 bearing mice treated with Flavonoid (300mg/kg B.W) orally/ daily dose-30 days.

2nd group: (n=3) AM3 bearing mice alone as positive control group.

3rd group: (n=5) Flavonoid (300mg/kg B.W) orally alone/ daily dose-30 days.

4th group: (n=5) D.W., The negative control group.

4-Histopathological examination: the specimens of lungs (1 cm³) were taken from sacrificed animal groups post 30 days the end of study, preserved in 10% formalin until paraffin blocking sectioning (4).

Results of lung Histopathology: investigated significant microscopic lesions in the pulmonary tissues of mice treated with flavonoid; characterized by necrotic bronchiolitis in mice treated with flavonoid only, and peri-bronchiolar focal infiltration of mononuclear cells (**figures-1&2**), thickening of alveolar walls due to congestion of

alveolar capillaries mixed with edematous-eosinophilic fluid and dilated alveolar capillaries which contained mononuclear cells (**figure-3**), few infiltration of mononuclear cells and proliferation of pulmonary macrophages seen in alveolar lumen and inter-alveolar septa (**figure-4**), long folding-like appearance of hyperchromatic epithelial cells of bronchioles (**figure-5**), eosinophilic mucinous material secreted in the lumen and heavy perivascular infiltration (**figure-6**).

In bearing tumor-treated flavonoid there were focal aggregations of mononuclear cells; peribronchiolar and interalveolar septa (**figures-7&8**), congested pulmonary blood vessels and contained mononuclear cells (**figure-9&10**), no infiltration or invasion of tumor cells in lungs during apigenin treatment or metastatic cells.

In tumor group; the dilated blood vessel lodged with a mass of tumor cells (**figure-11&12**), perivascular cuffing, fibrin and intravascular edema, peribronchiolitis with emphysema (**figure-13**).

All microscopic lesions were compared with **negative control group** which appeared no significant lesions (NSL).

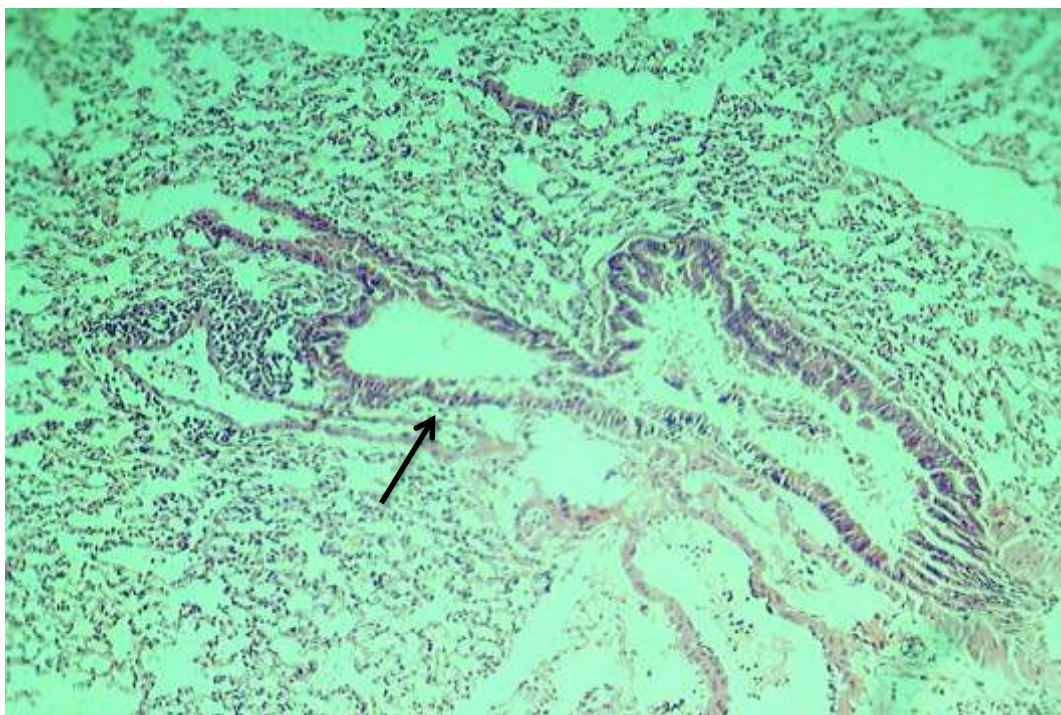


Figure-1: Histopathologic section in mouse treated with flavonoid (300mg/kg-b.w/30 days orally), showed necrotic bronchiolitis (→) H&E stain, 20X).

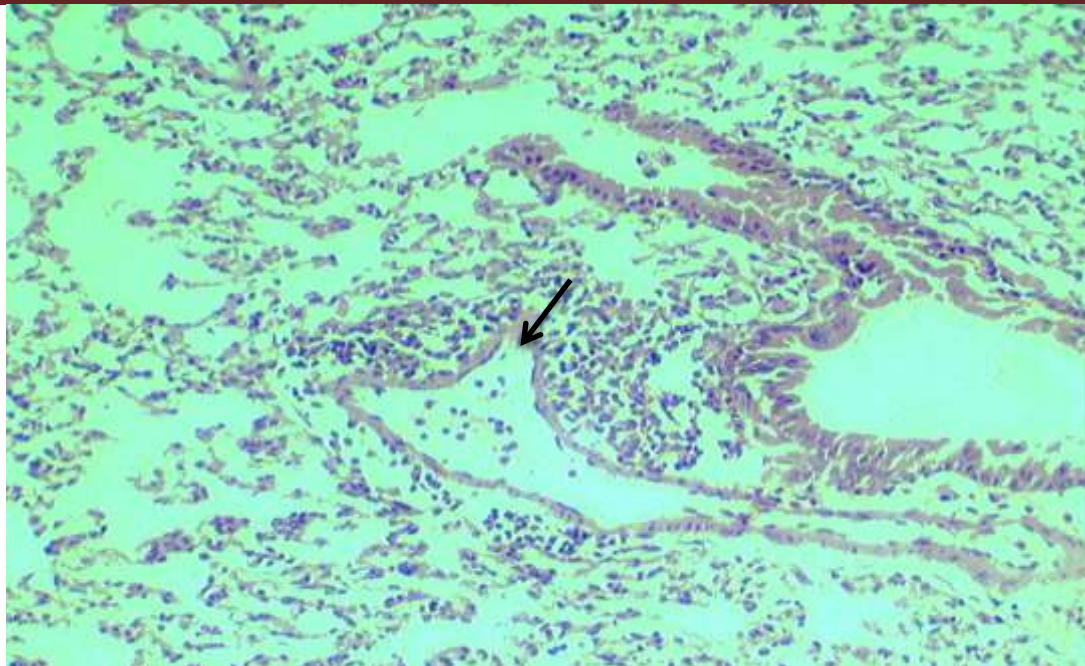


Figure-2: High magnification of figure-1 showed focal perivascular cuffing (→) (H&E stain, 40X).

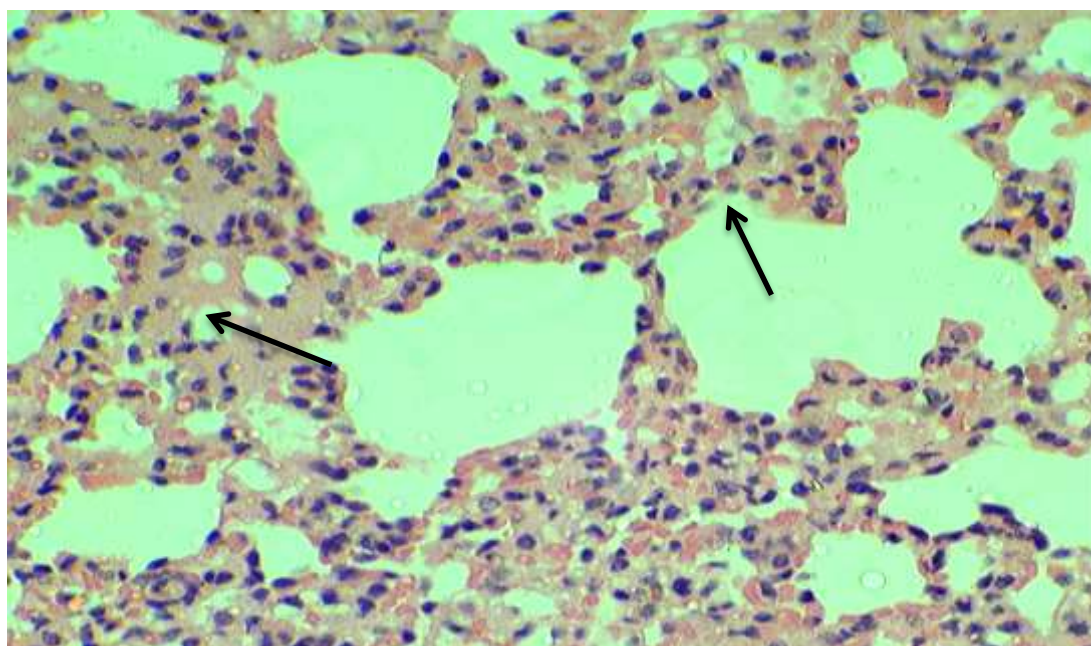


Figure-3: Histopathology section in mouse-bearing tumor treated with flavonoid, showed thickened alveolar walls, interstitial edema and lymphocytes infiltration (→) (H&E stain, 40X).

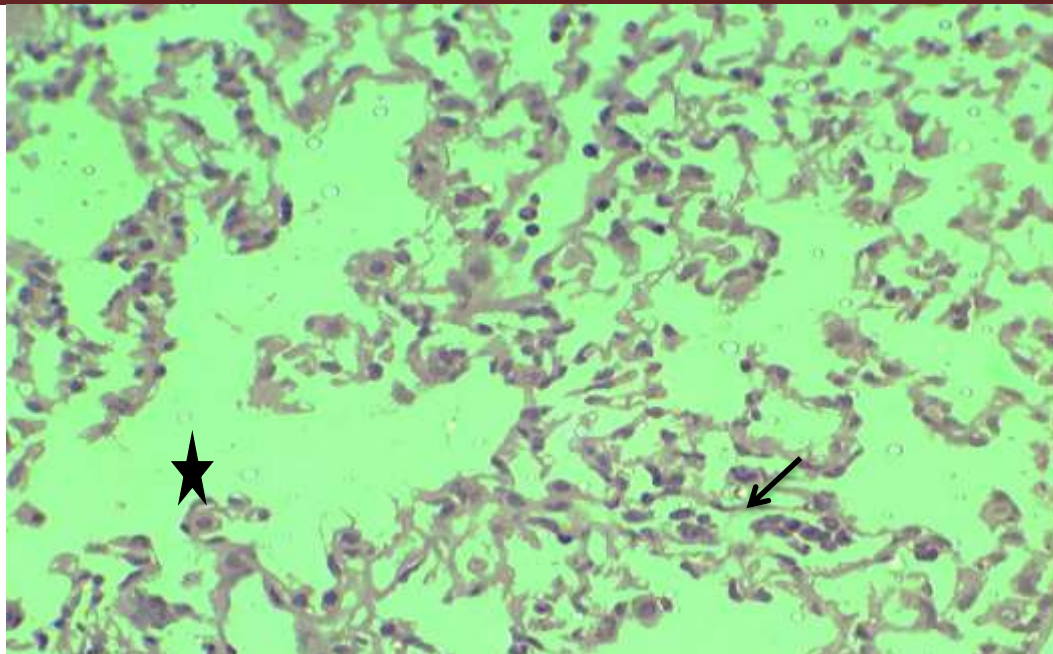


Figure-4: Histopathology section in mouse-bearing tumor treated with flavonoid, showed pulmonary macrophages (↙) and emphysema (★) (H&E, stain, 20X).

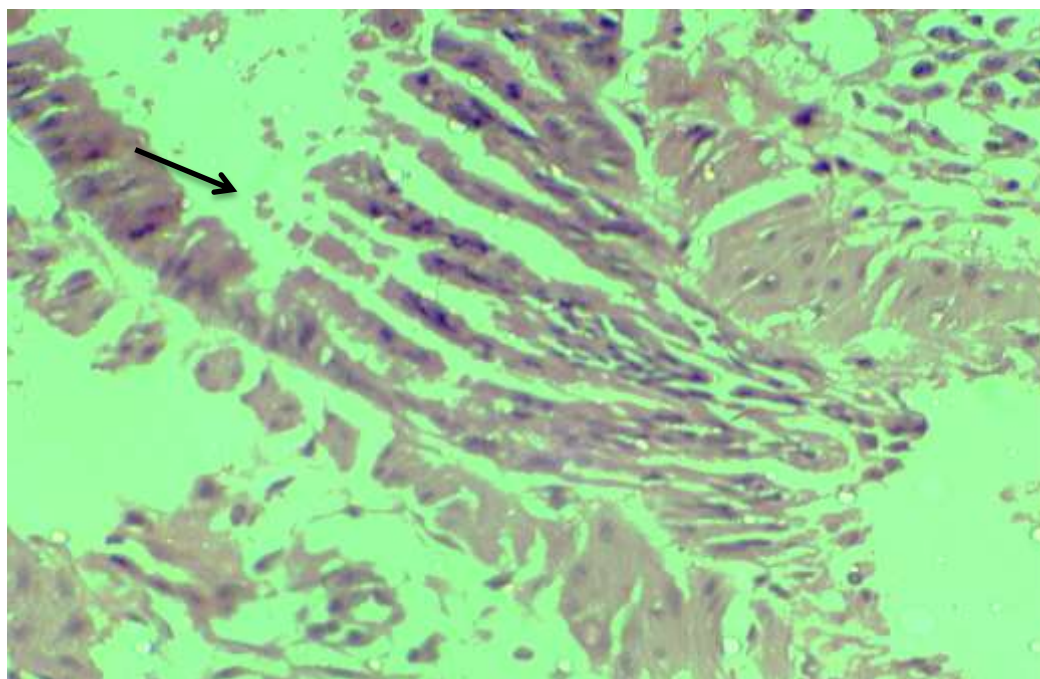


Figure-5: histopathology section in mice treated with flavonoid, showed long folding epithelium of bronchoiles (→) (H&E stain, 40X).

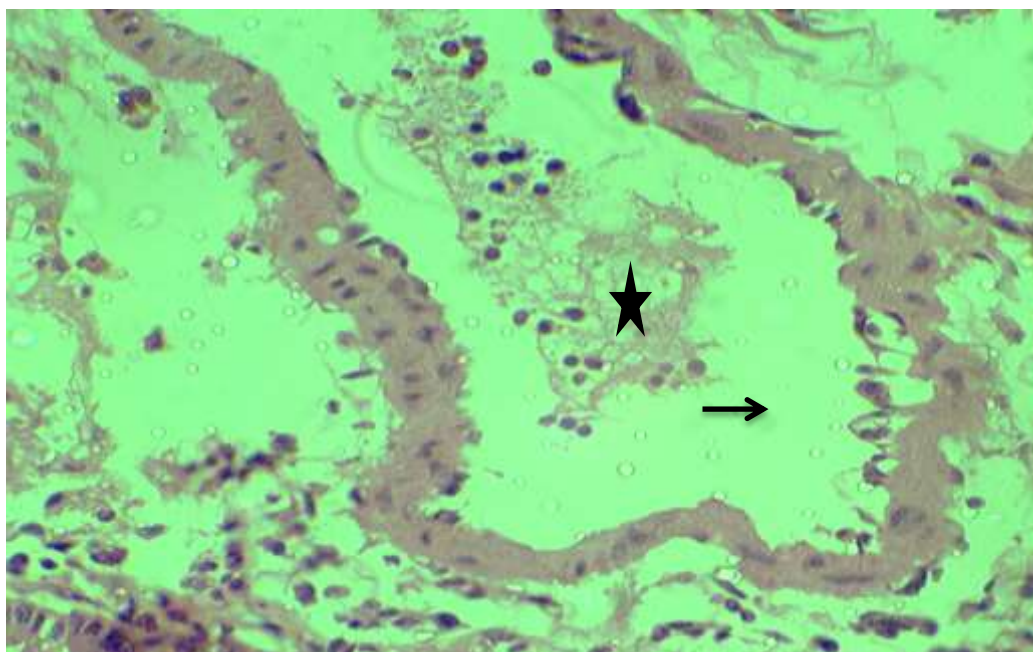


Figure-6: Histopathologic section in mouse-bearing tumor treated with flavonoid (300 mg/kg b.w), showed great dilation of pulmonary blood vessel, enlarged vacuolated endothelial cells (→) contained mononuclear cells with fibrin (★)(H&E stain, 40X).

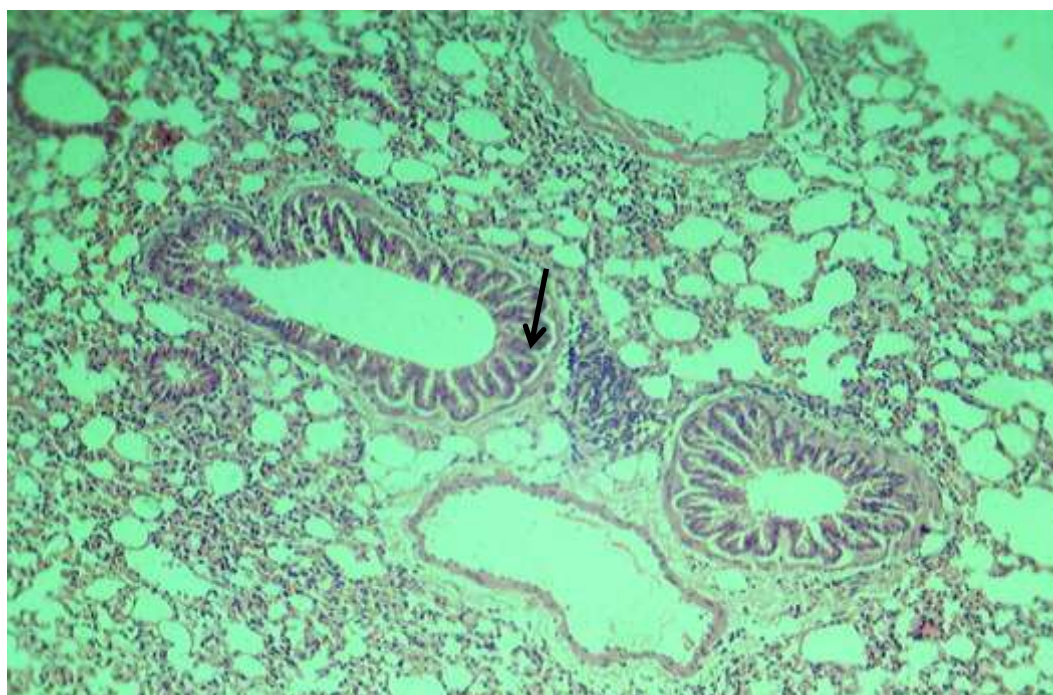


Figure-7: Histopathologic section in mouse-bearing tumor treated with flavonoid (300 mg/kg b.w), showed peribronchial follicular ag-

→

gregation of lymphocytic cells () and interalveolar septa (H&E stain, 20X).

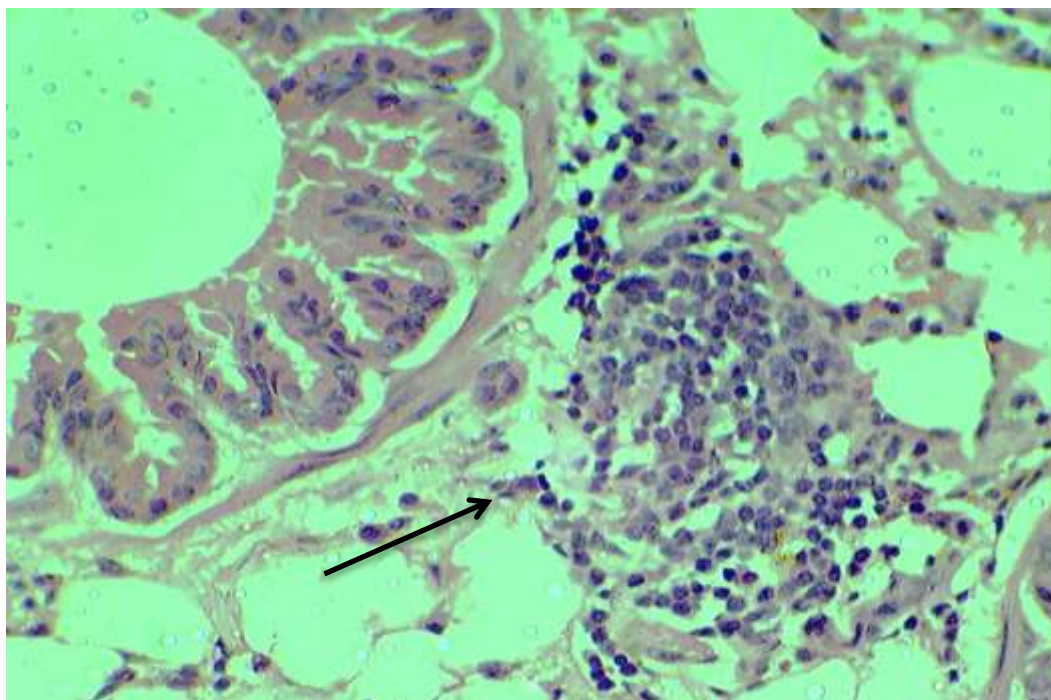


Figure-8: High magnification of figure-3, showed follicular peribronchovascular aggregation of lymphocytic cells (→) (H&E stain, 40X).

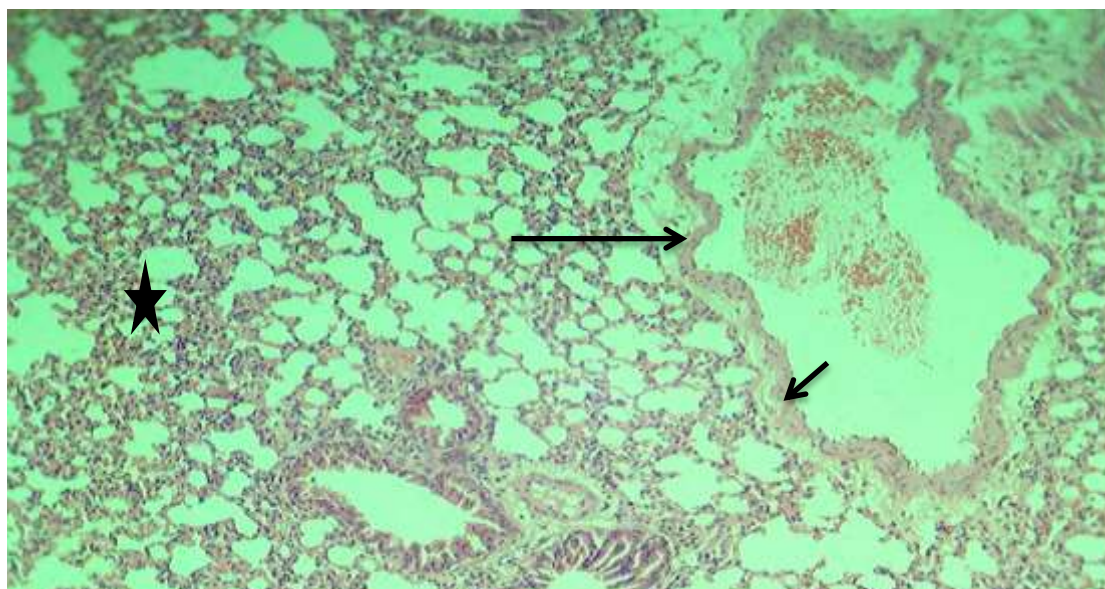


Figure-9: Histopathologic section in mouse-bearing tumor treated with flavonoid, showed intra and perivascular edema and inflammatory cells (→) and emphysema (H&E stain, 40X).

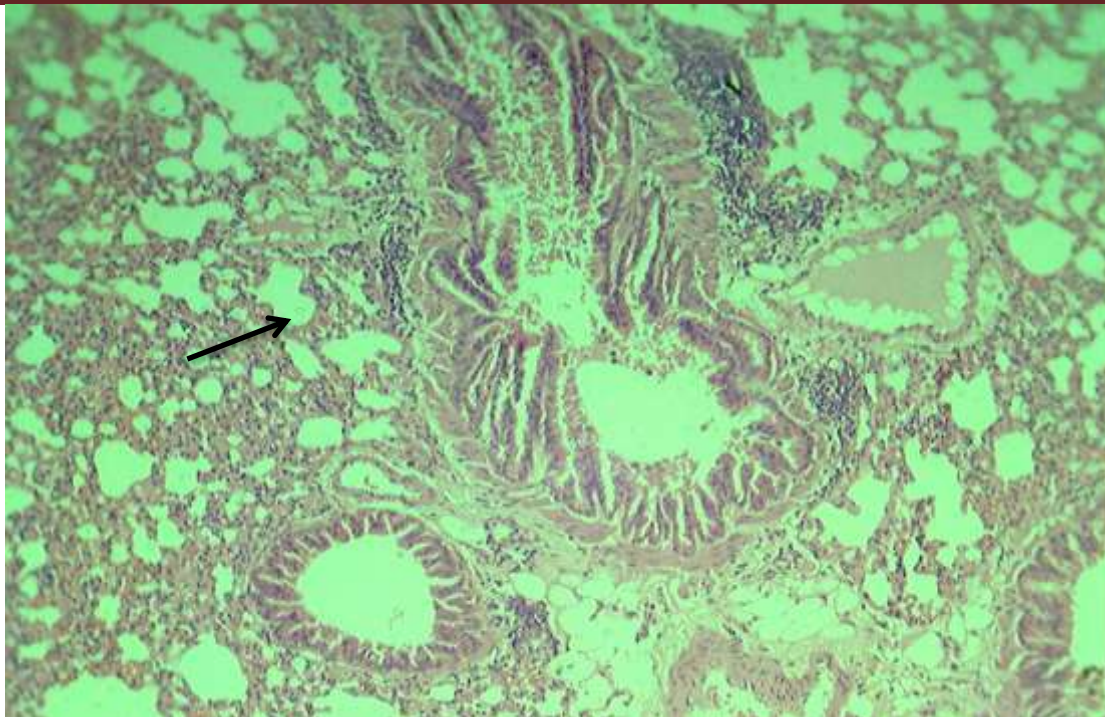


Figure-10: Histopathologic section in mouse-bearing tumor treated with flavonoid, showed peribronchiolitis (—→) and epithelial folding with mucinous secretion in lumen (H&E stain, 20X).

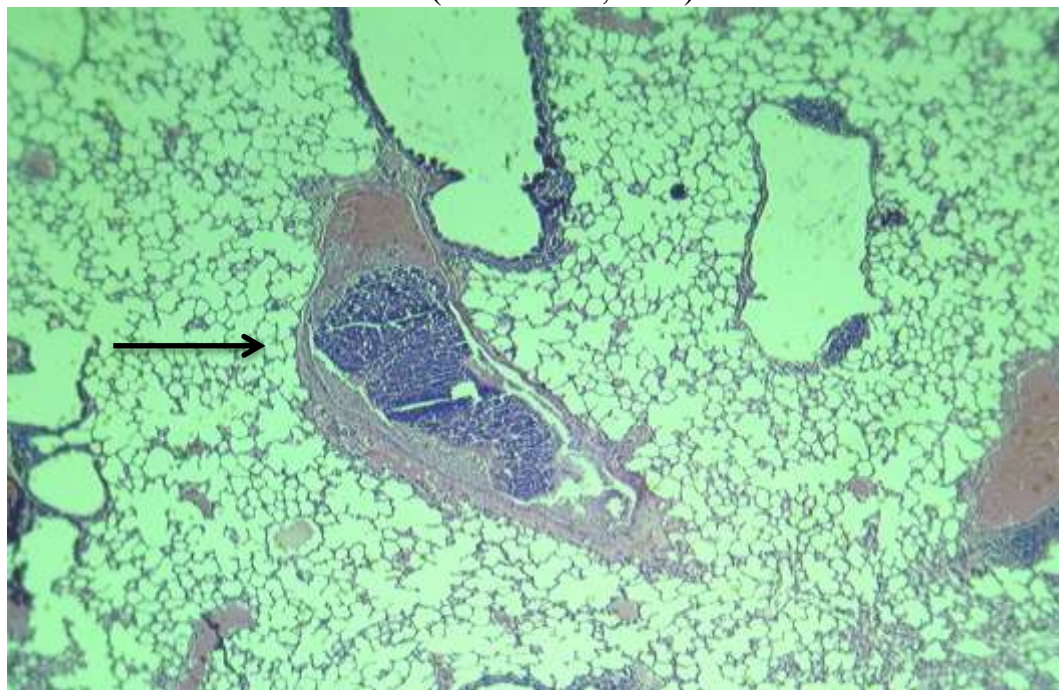


Figure-11: Histopathologic section in mouse-bearing tumor, showed lodged tumor-thrombus of pulmonary blood vessel (—→) and severe emphysema (H&E stain, 10X).

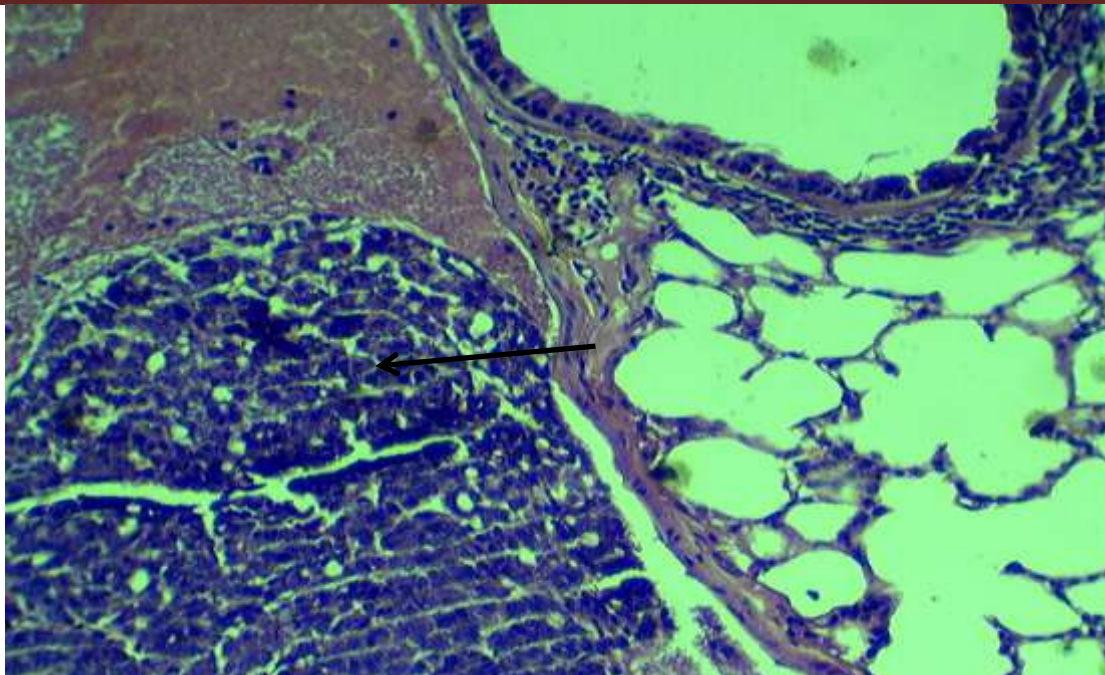


Figure-12: high magnification of 10, showed pleomorphic tumor cells mixed with inflammatory cells occlude the dilated pulmonary blood vessel (←) (H&E stain, 40X).

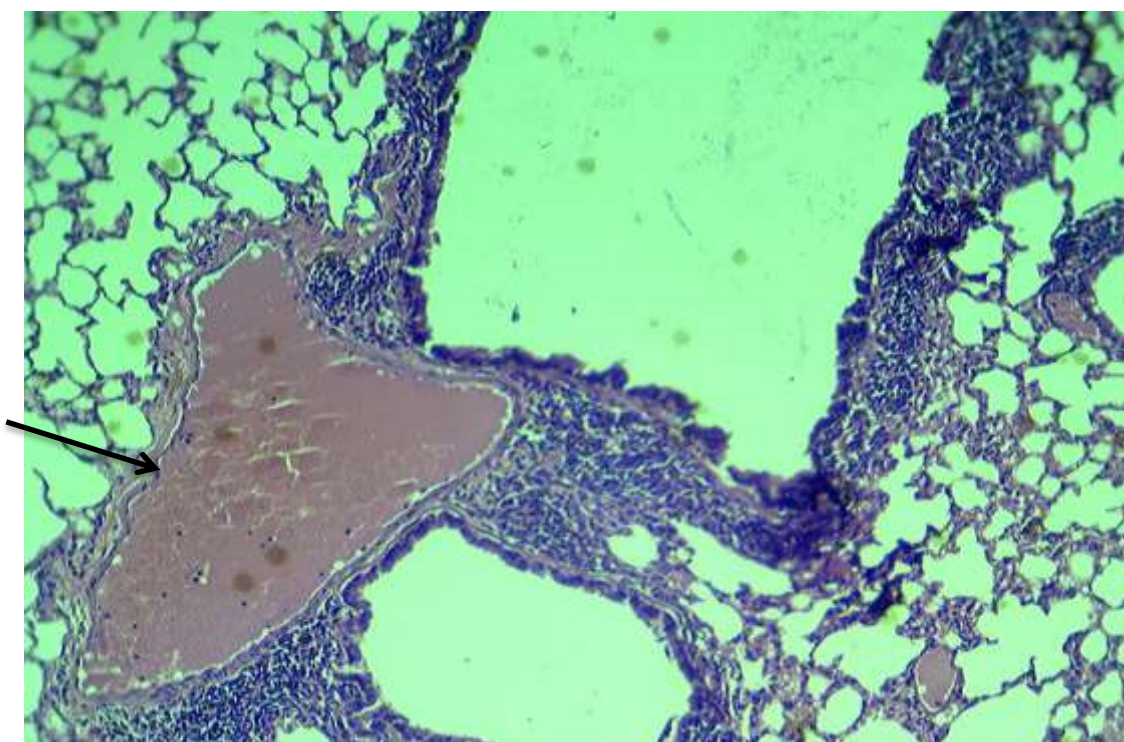


Figure-13: histopathologic section in tumor-bearing mouse, showed severe peribronchiolitis and fully intravascular edema (→) (H&E stain, 20X).

Discussion:

Flavonoids; plant phenolic compounds constituting the largest class of non-essential nutrients in our diet, have been shown to have anti-cancer and anti-inflammatory activities (8&3). Apigenin regulates inflammatory mediators, including IL-1 α and TNF- α , in both human and mouse cell lines (13 &6), that may agree with present study which revealed moderate infiltration of mononuclear cells (lymphocytes and macrophages) may due to the oxidative activity of flavonoid that reduced the toxic effects of tumor cells from damaged the tissues, which occurred in necrotic changes of lining epithelial cells.

Several studies suggest that flavonoids may act as antioxidants, free radical scavengers or radioprotectors (9). Flavonoids possess an interesting anti-inflammatory profile, related to their capability to scavenge various oxidizing species i.e. superoxide anion (O₂⁻), hydroxyl radical or peroxy radicals (5). Superoxide dismutase, a known scavenging agent of superoxide radicals, is believed to act as a first line of antioxidant defense against oxygen free radicals that mediate cytotoxicity or cell death. Results of (2) showed significantly high mean value for SOD activity after flavonoids injection than its value in normal control group. SOD levels in the flavonoids-radiation group was significantly higher compared to the radiation control group, may hypothesized that the efficacy of flavonoids in preventing radiation damage may depend on the elevation of SOD. No significant inflammatory reaction in lung tissues treated with flavonoid agreed with (10) who revealed that apigenin reduced pro-inflammatory cytokine production by inhibiting NF- κ B phosphorylation in macrophages and reduced neutrophil chemotaxis *in vitro*.

In tumor-treated with apigenin no tumor cells infiltration, invasion or associated cells from macrophages or lymphocytes, the significant lesion was lymphocytic infiltration, may agree with several studies demonstrated the anticarcinogenic properties of apigenin through regulation of cellular response to oxidative stress and DNA damage, suppression of inflammation and angiogenesis, retardation of cell proliferation, and induction of autophagy and apoptosis (1).

Conclusion: *the significant efficacy of apigenin in elimination, and invading prevention of mammary adenocarcinoma AM3 in mice.*

References:

- 1- Alol, L.H.; Al-Mzaien, K.A. and Hussein, S.M. (2012). The Promising Anticancer Efficacy of Parsley Seeds Flavonoid (Apigenin) in induced mammary adenocarcinoma (AMN3) in mice. *Journal of Physiological and Biomedical Sciences*; 25(1): 5-12. Available online at www.j-pbs.org
- 2- Alol, L.H., Al-Mzaien, K.A., Hussein, S.H.M. (2009). Anticancer effect of flavonoid (apigenin) extracted from Parsley (*Petroselinum sativum*) seeds in cancer cells lines. *Iraqi J Cancer*. 2(1).
- 3- Garcia-Lafuente, A.; Guillamon, E.; Villares, A.; Rostagno, M.A.; Martinez, J.A. (2009). Flavonoids as anti-inflammatory agents: Implications in cancer and cardiovascular disease. *Inflamm. Res.*, 58: 537–552.

- 4- Godkar, P.B. and Godkar, D.P. (2003). Textbook of Medical Laboratory Technology, 2ed edition, Bahalani Publishing House, Mumbai, India. pp: 393-1014.
- 5- Harborne, J.B. and Williams, C.A. (2000). Advances in flavonoid research since 1992. *Phytochemistry*, vol, 55: 481-504.
- 6- Kowalski, J.; Samojedny, A.; Paul, M.; Pietsz, G.; Wilczok, T. (2005). Effect of apigenin, kaempferol and resveratrol on the expression of interleukin-1b and tumor necrosis factor- α genes in j774.2 macrophages. *Pharmacol. Rep.*, vol, 57: 390–394.
- 7- Lippman, S.M. and Hong, W.K. (2002). Cancer prevention science and practice. *Cancer Res.* vol, 62:5119-5125.
- 8- Middleton, E. (1996). The flavonoids as potential therapeutic agents. In Immunopharmaceuticals; Kimball, E.S., ed., CRC Press: Boca Raton, FL, USA,; pp. 227–257.
- 9- Martins, E.A.; Chubatsu, L.S. and Meneghini, R. (1991). Role of antioxidants in protecting cellular DNA from damage by oxidative stress. *Mutat Res*, vol, 250.pp: 95-101.
- 10- Nicholas, C.; Batra, S.; Vargo, M.A.; Voss, O.H.; Gavrilin, M.A.; Wewers, M.D.; Guttridge, D.C.; Grotewold, E. and Doseff, A.I. (2007). Apigenin blocks lipopolysaccharide-induced lethality in vivo and pro-inflammatory cytokines expression by inactivating NF- κ B through the suppression of p65 phosphorylation. *J. Immunol.*, vol, 179, 7121–7127.
- 11- Sung, B.; Chung, H. Y. and Kim, N. D. (2016). Role of Apigenin in Cancer Prevention via the Induction of Apoptosis and Autophagy. *Journal of cancer prevention*, vol. 21, No. (4), December: 216-226.
- 12- Wang, J.; Heng-Wei, X.; Li, B-S.; Zhang, J. and Cheng, J. (2012). Preliminary Study of Protective Effects of Flavonoids against Radiation-induced Lung Injury in Mice. *Asian Pacific Journal of Cancer Prevention*, vol, 13:6441-6446.
- 13- Woo, E. R.; Pokharel, Y.R.; Yang, J.W.; Lee, S.Y. and Kang, K.W. (2006). Inhibition of nuclear factor- β activation by 21,811-biapigenin. *Biol. Pharm. Bull.*, vol, 29: 976–980.